Histopathology of the Matrix Patch

Matthias Sigler

Pediatric Cardiology and Intensive Care Medicine
Heart Center, Georg August University, Göttingen
Germany

Autotissue Round Table Meeting Berlin, September 1st, 2018

UNIVERSITÄTSMEDIZIN GÖTTINGEN : UMG

Herz Zentrum Göttingen

Histopathology of the Matrix Patch

Disclosures

Autotissue
Admedus, Gore Medical

Autotissue Round Table Meeting

Berlin, September 1st, 2018

UNIVERSITÄTSMEDIZIN GÖTTINGEN : UMG

Herz Zentrum Göttingen

Histopathology of the Matrix Patch

Biocompatibility of Cardiovascular Implants

- Histology of an explanted Matrix-Patch
- How it all began…
- Analysis of other Patchmaterials
- Matrix-Patch: Göttingen experience
- Summary
- 

Autotissue Round Table Meeting

Berlin, September 1st, 2018

UNIVERSITÄTSMEDIZIN GÖTTINGEN UMG

Herz Zentrum Göttingen

Histopathology of an explanted Matrix-Patch

Macroscopic view

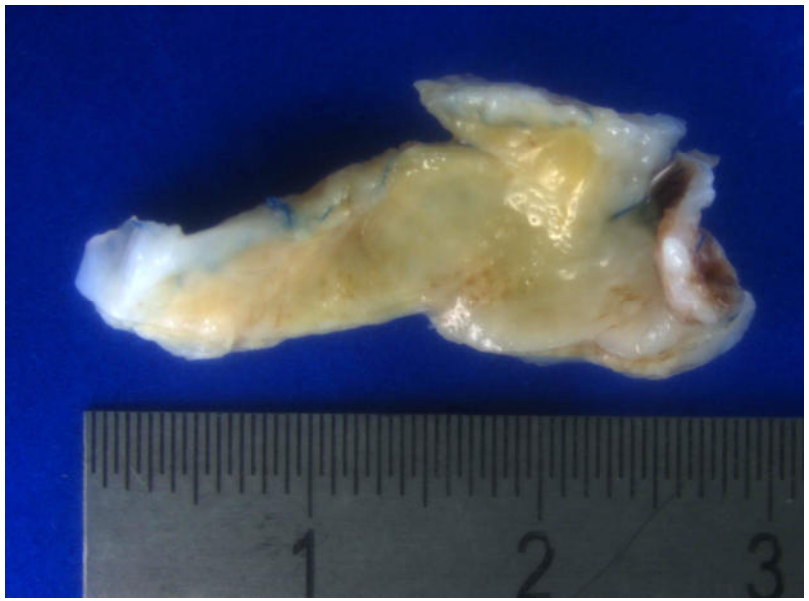

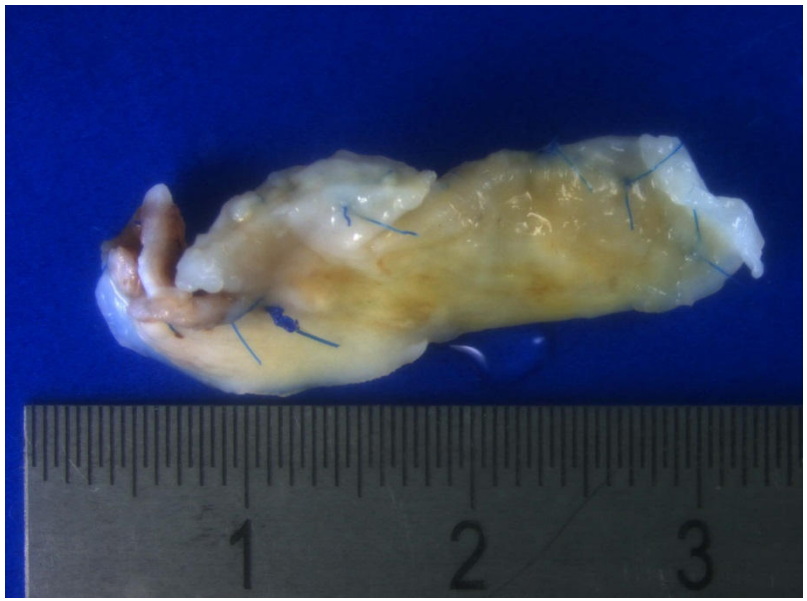

Posterior MK leaflet, augmented with Matrix Patch
Explantation after 5 months due to mitral regurgitation and LV dysfunction

Histopathology of an explanted Matrix-Patch

Histology

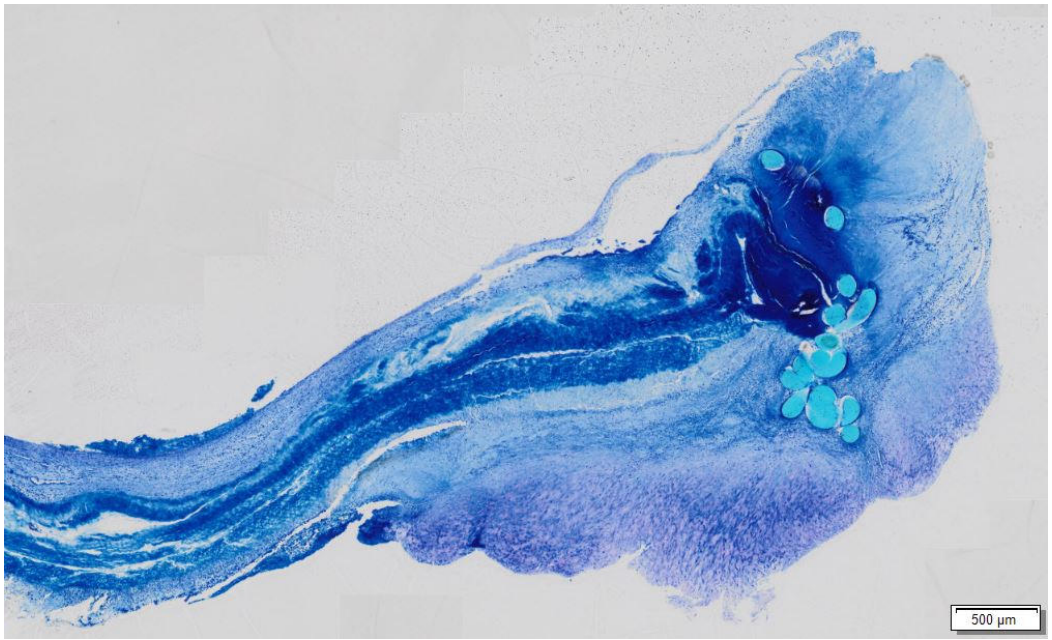

Standard staining
Richardson blue

Posterior MK leaflet, augmented with Matrix Patch
Explantation after 5 months due to mitral regurgitation and LV dysfunction

Histopathology of an explanted Matrix-Patch

Histology

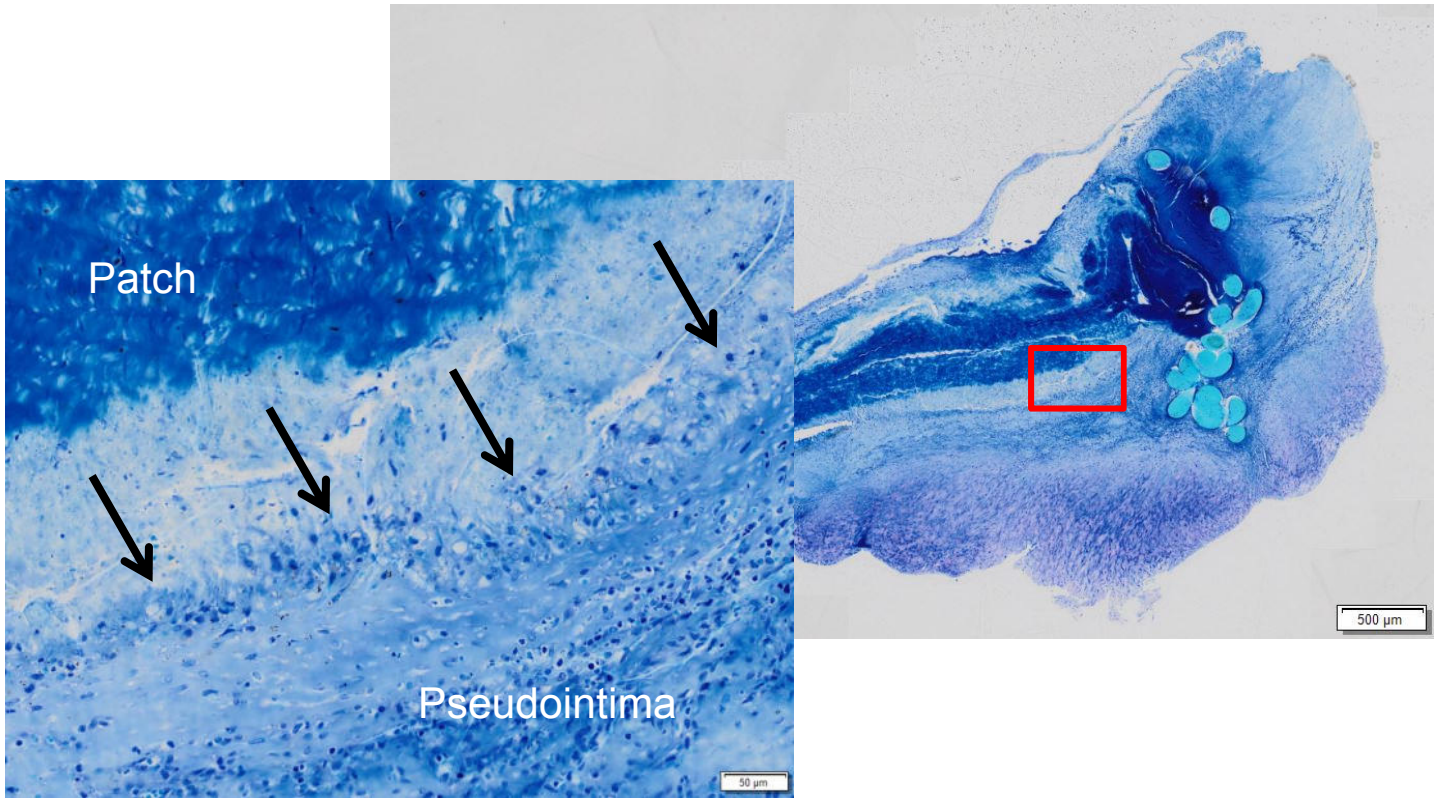

UNIVERSITÄTSMEDIZIN GÖTTINGEN UMG

Herz Zentrum Göttingen

Histopathology of an explanted Matrix-Patch

Histology

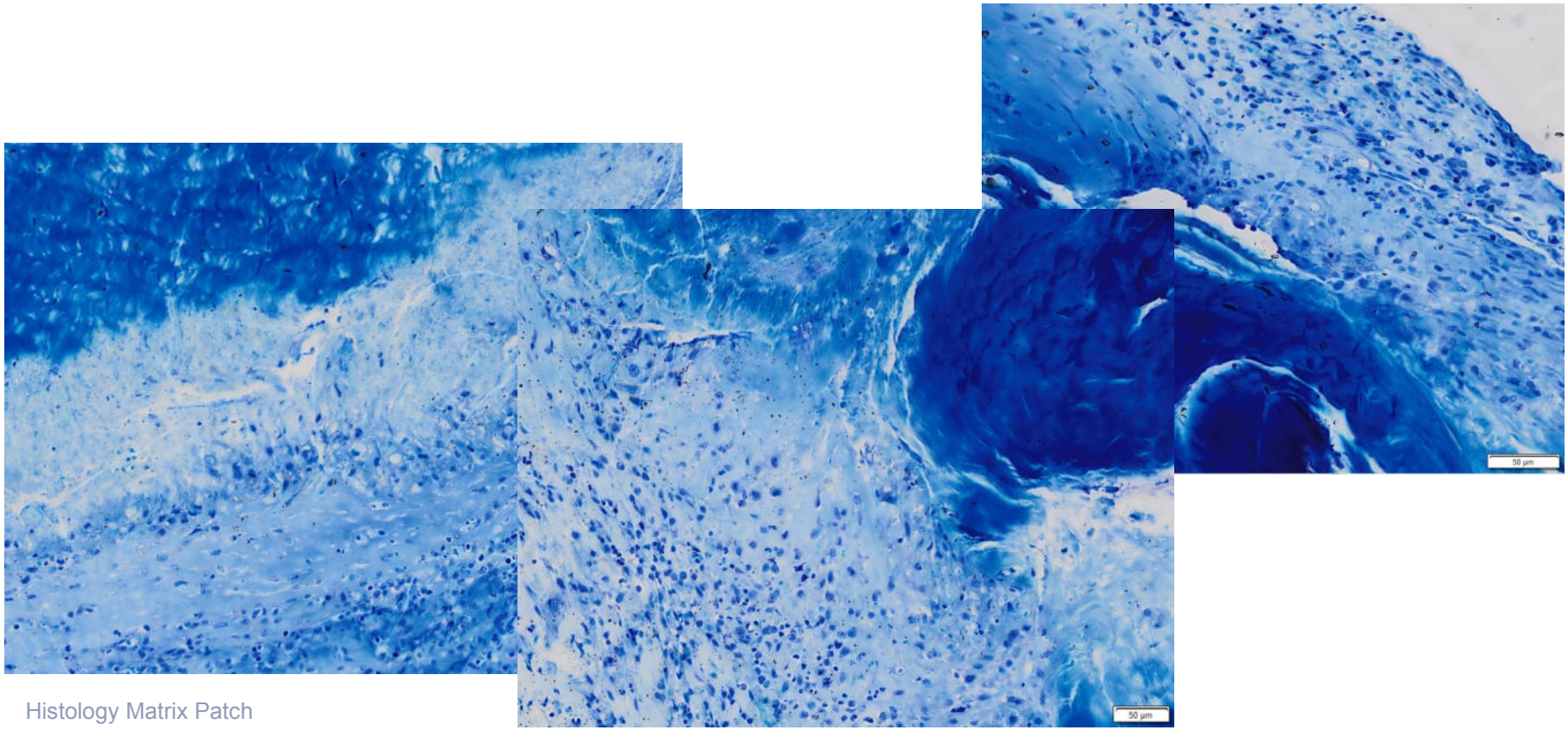

Histology Matrix Patch

UNIVERSITÄTSMEDIZIN GÖTTINGEN : UMG

Herz Zentrum Göttingen

Histopathology of an explanted Matrix-Patch

Histology - Immunohistochemistry

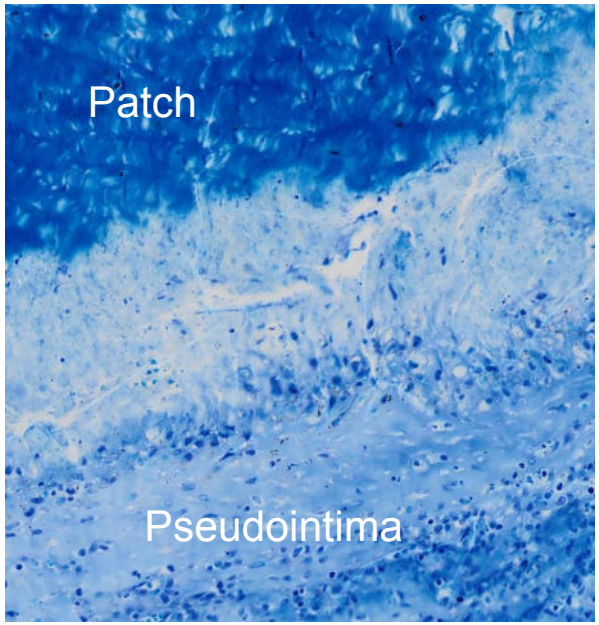

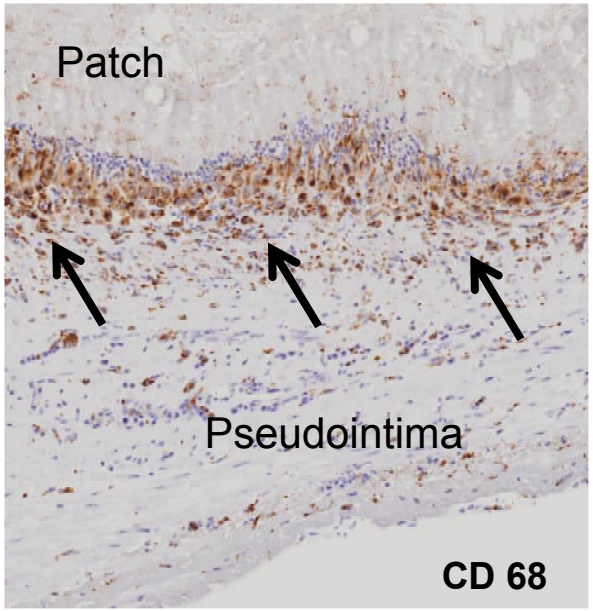

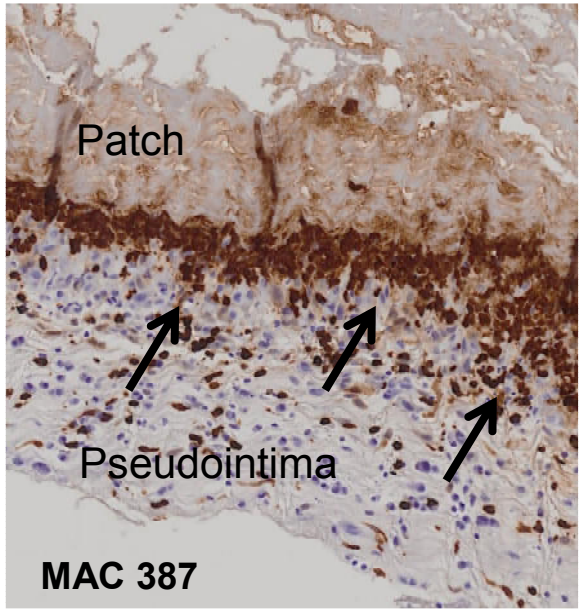

UNIVERSITÄTSMEDIZIN GÖTTINGEN UMG

Herz Zentrum Göttingen

Histopathology of an explanted Matrix-Patch

Histology - Immunohistochemistry

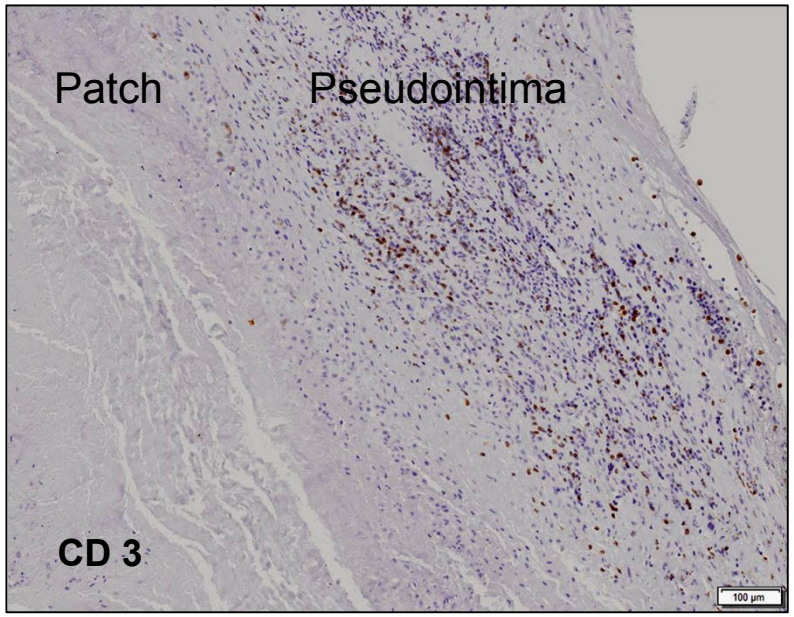

T-lymphocytes

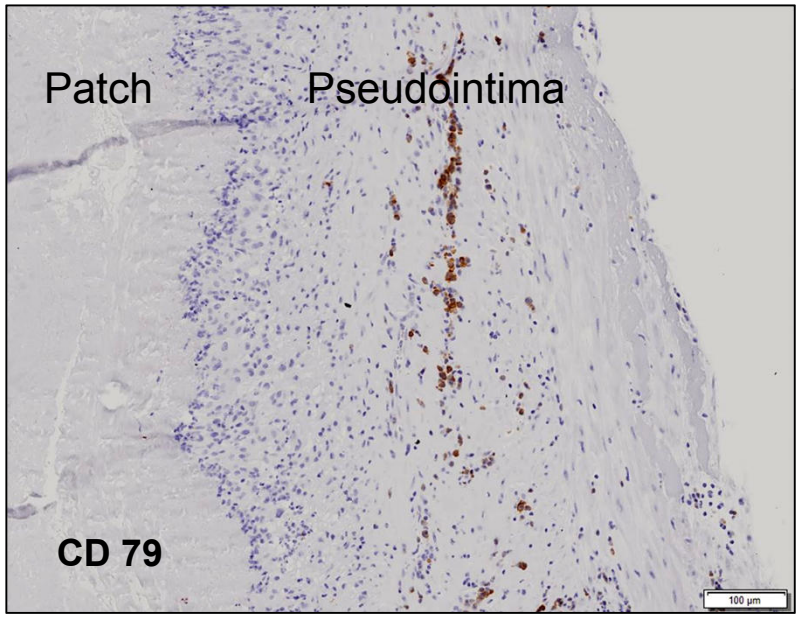

B-lymphocytes

Histopathology of an explanted Matrix-Patch

Histology - Immunohistochemistry

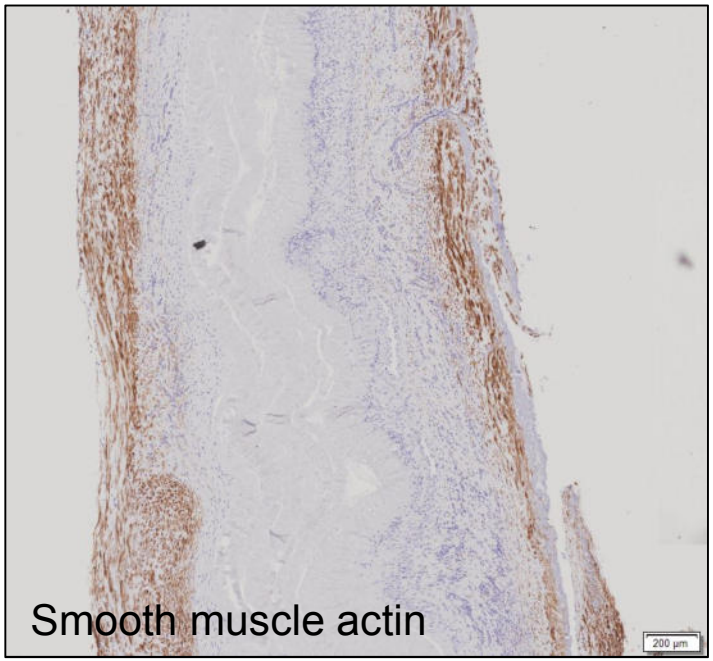

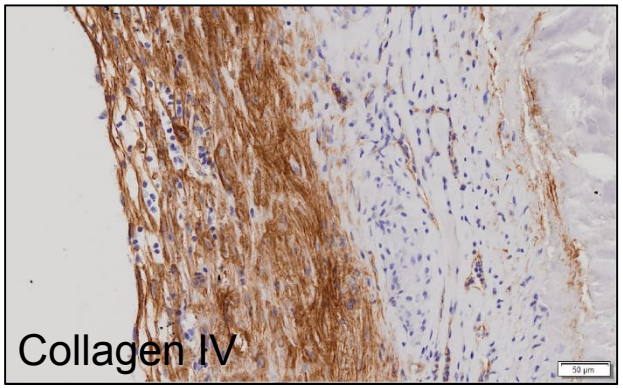

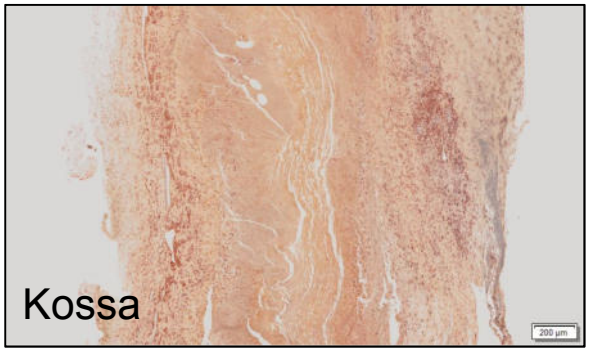

Kossa´s stain: Calcifications = black

UNIVERSITÄTSMEDIZIN GÖTTINGEN : UMG

Herz Zentrum Göttingen

Histopathology of an explanted Matrix-Patch

Posterior MK leaflet, augmented with Matrix Patch
Explantation after 5 months due to mitral regurgitation and LV dysfunction

- Some Pseudointimaproliferation
- Macrophage wall
- Some lymphocytic infiltration (predominantly T-cells)
- No granulocytes
- No cell ingrowth into patch material
- No calcification

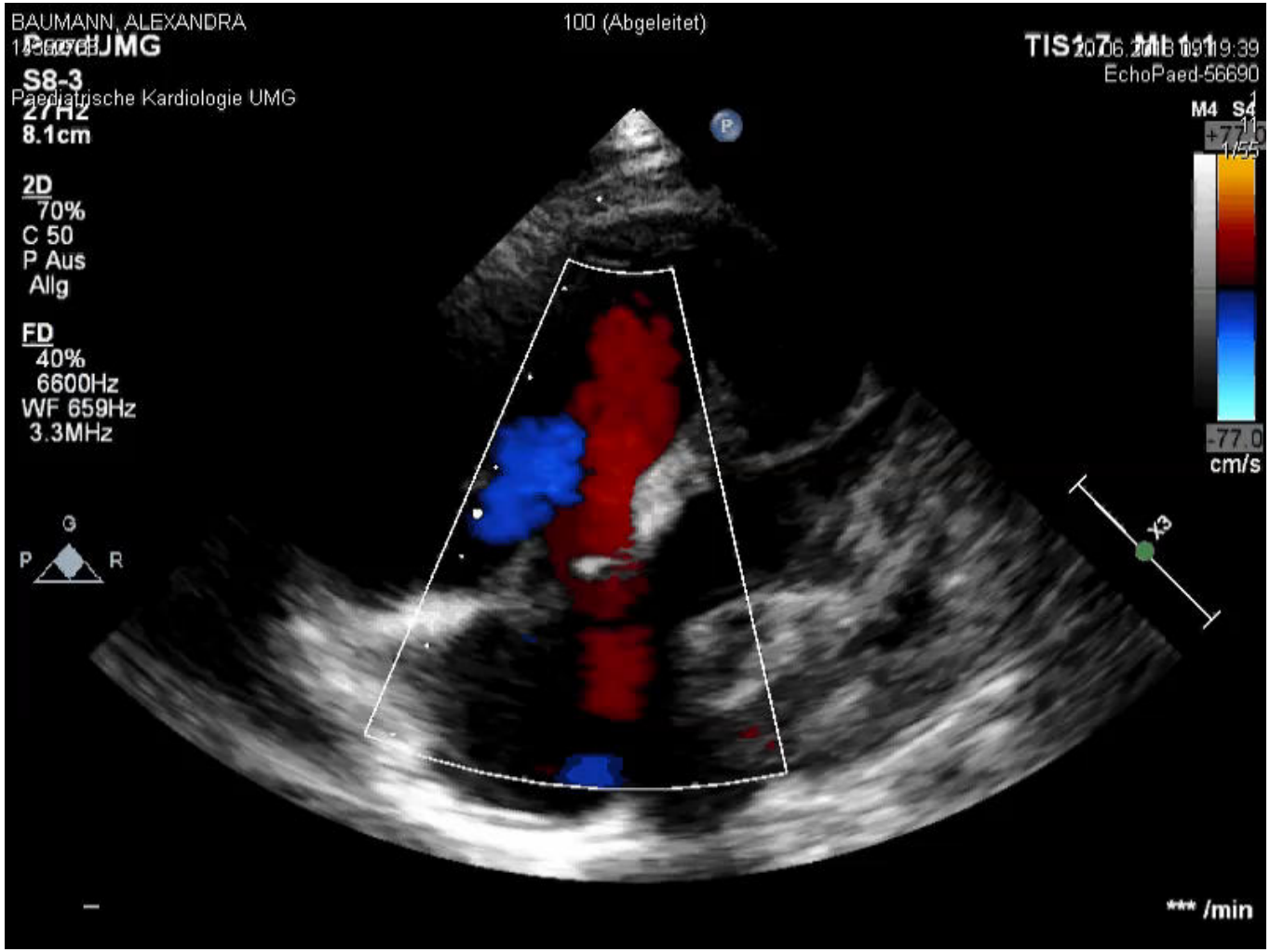
BAUMANN, ALEXANDRA
100 (Abgeleitet)
S8-3
Paediatrische Kardiologie UMG
27Hz
8.1cm
2D
70%
C 50
P Aus
Allg
FD
40%
6600Hz
WF 659Hz
3.3MHz
EchoPaed-56690
M4 S4
-77.0
cm/s
X3
G
P
R
*** /min

How it all began…

UNIVERSITÄTSMEDIZIN GÖTTINGEN UMG

Herz Zentrum Göttingen

UNIKLINIK RWTH AACHEN

IZKF BIOMAT





Heart surgery



Cardiology

Pathology

UNIKLINIK RWTH AACHEN

IZKF BIOMAT



UNIVERSITÄTSMEDIZIN GÖTTINGEN UMG

Herz Zentrum Göttingen



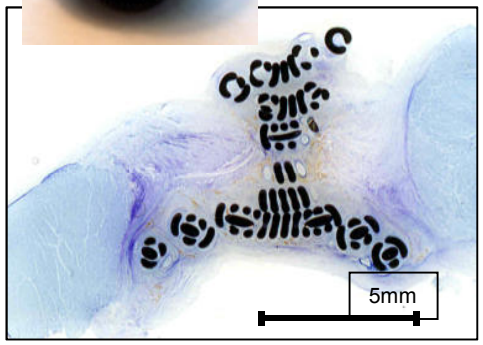

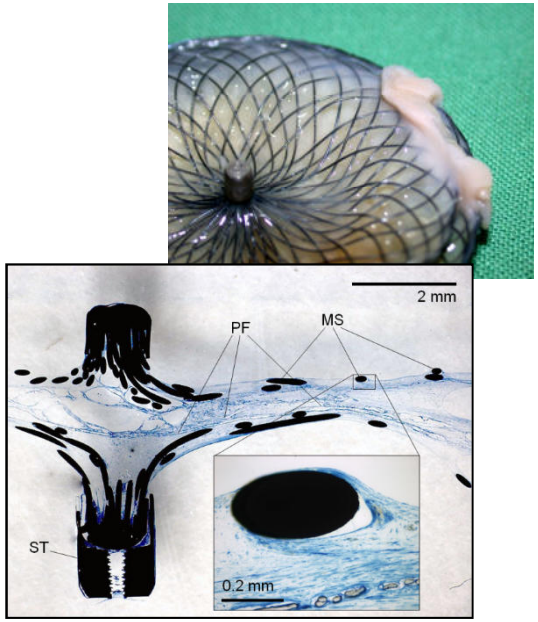



Analysis of other Patchmaterials

UNIVERSITÄTSMEDIZIN GÖTTINGEN : UMG

Herz Zentrum Göttingen

Long term in vivo reactions to PTFE and polyester in the cardiovascular system

Results:

- More lymphocytes/macrophages/foreign body reaction in explants containing polyester vs. PTFE
- Calcifications in all explants with implantation times > 7 years
- More calcifications locally related to polyester vs. PTFE

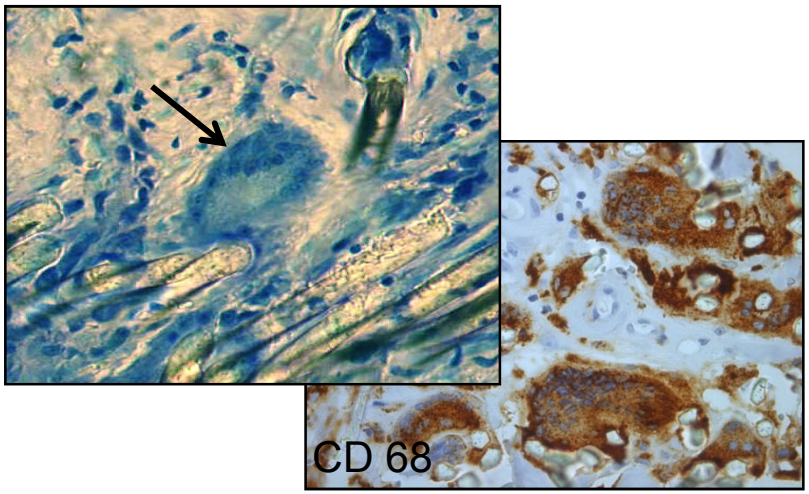

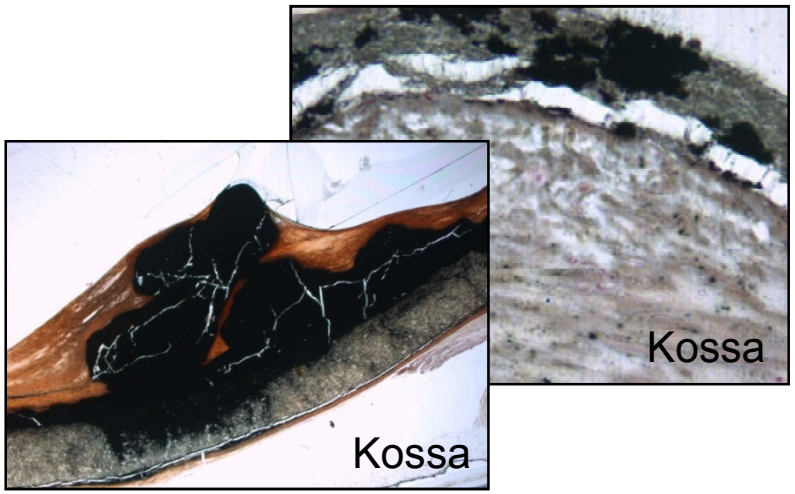

Long term in vivo reactions to PTFE and polyester in the cardiovascular system

Summary:

- **Chronic inflammatory reactions in all implants containing textile fibres, Polyester > PTFE**
- **Significant calcifications in all implants containing textile fibres > 7 years after implantation, Polyester > PTFE**

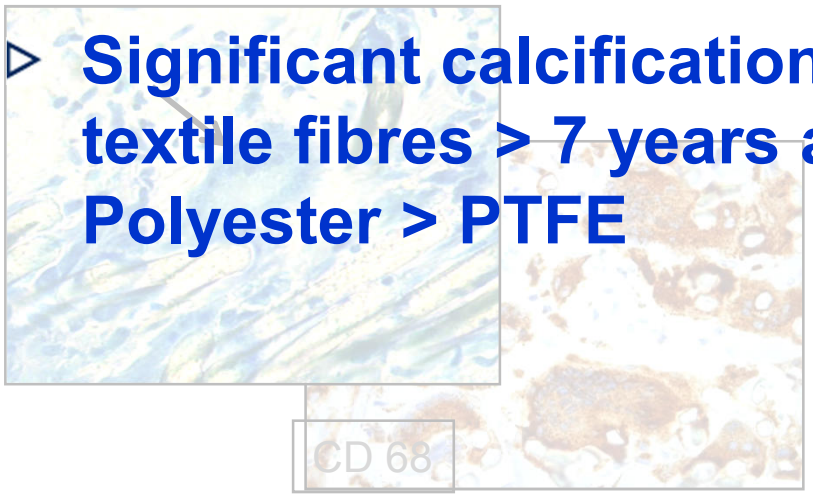



Analysis of other Patchmaterials

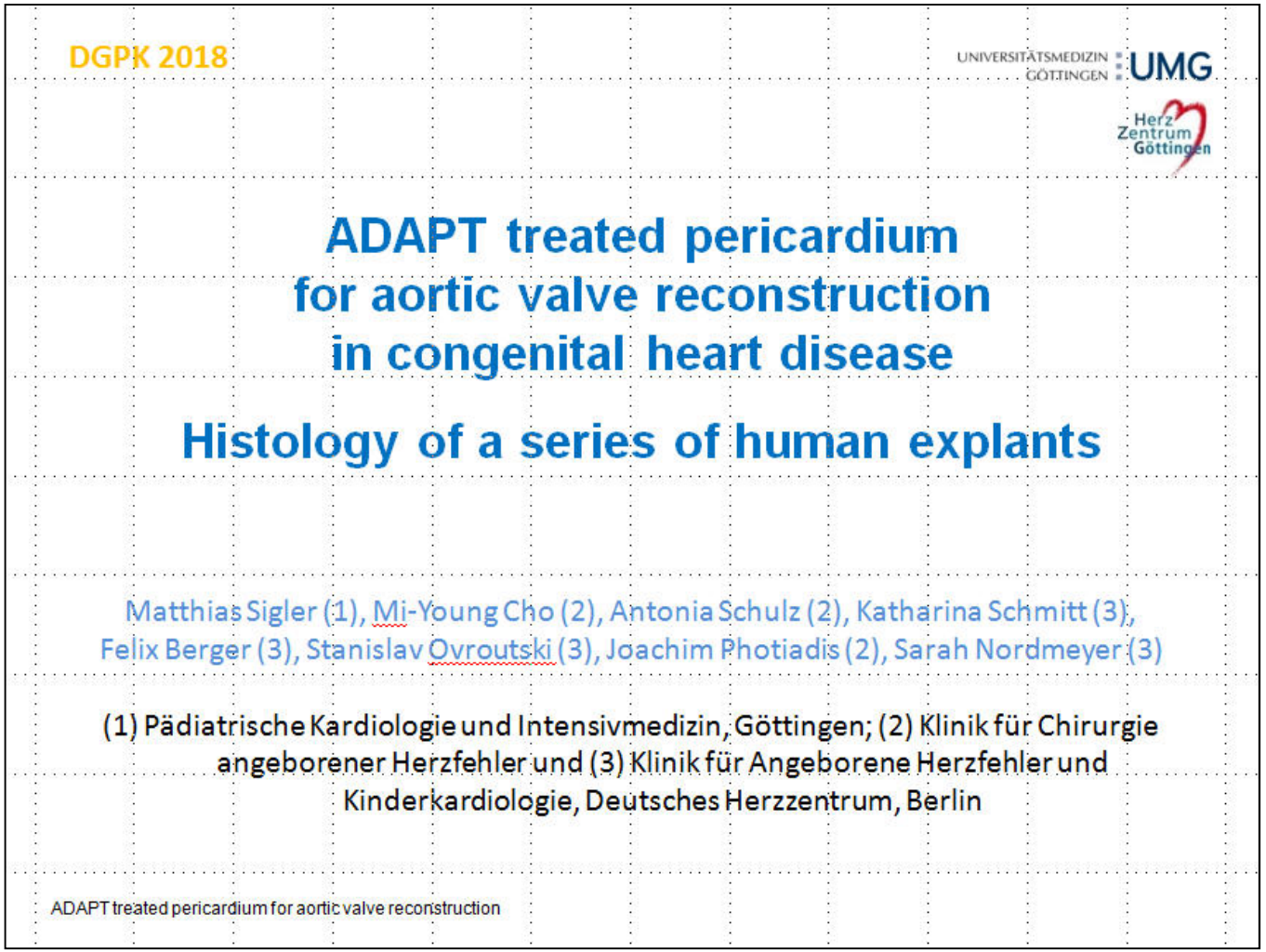

DGPK 2018

UNIVERSITÄTSMEDIZIN GÖTTINGEN UMG

Herz Zentrum Göttingen

ADAPT treated pericardium for aortic valve reconstruction in congenital heart disease

Histology of a series of human explants

Matthias Sigler (1), Mi-Young Cho (2), Antonia Schulz (2), Katharina Schmitt (3), Felix Berger (3), Stanislav Ovroutski (3), Joachim Photiadis (2), Sarah Nordmeyer (3)

(1) Pädiatrische Kardiologie und Intensivmedizin, Göttingen; (2) Klinik für Chirurgie angeborener Herzfehler und (3) Klinik für Angeborene Herzfehler und Kinderkardiologie, Deutsches Herzzentrum, Berlin

ADAPT treated pericardium for aortic valve reconstruction

Analysis of other Patchmaterials

UNIVERSITÄTSMEDIZIN GÖTTINGEN UMG

Herz Zentrum Göttingen

Cardio Cel Patch - Inflammation

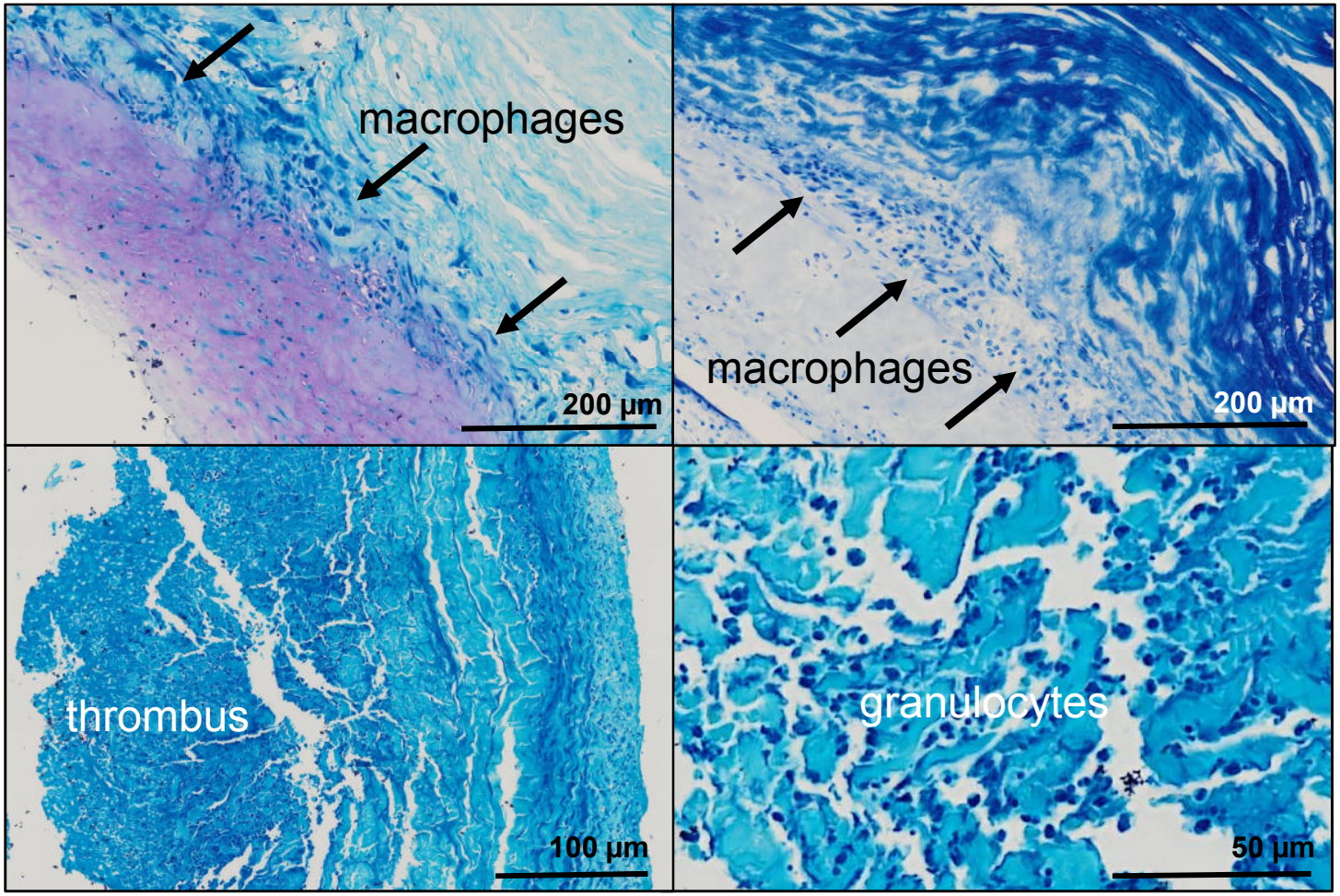

Analysis of other Patchmaterials

UNIVERSITÄTSMEDIZIN GÖTTINGEN UMG

Herz Zentrum Göttingen

Cardio Cel Patch - Calcifications

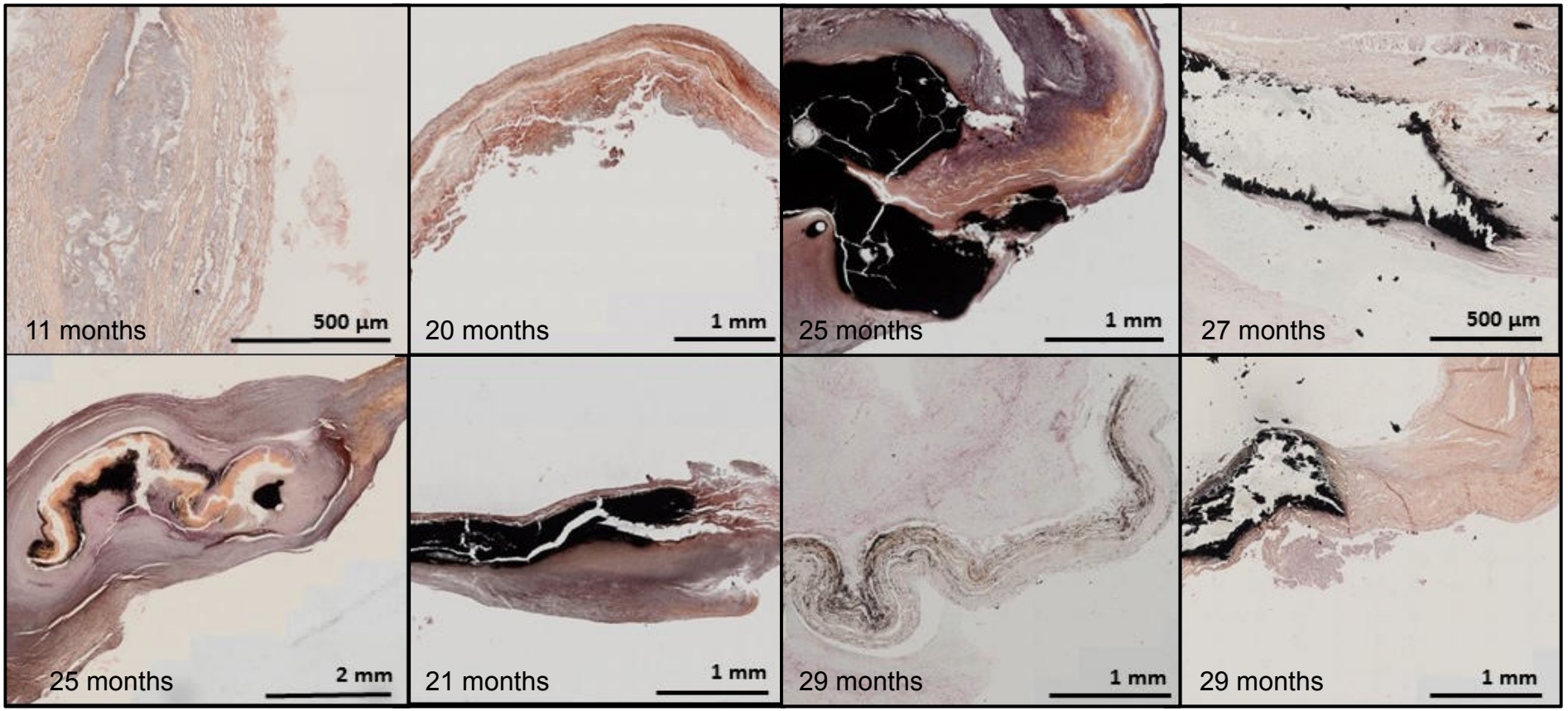

Kossa´s stain: Calcifications = black

histological

Matrix-Patch: Göttingen experience

Patient	Impl.-time (months)	Location	Reason for explantation
V. V.	3	Aortic arch	Stenosis
J. W.	5	Mitral valve	MI
D. S.	7	Aortic arch	Stenosis
M. M.	10	Aortic arch	Not patch related
A. R.	11	Tricuspid valve	Stenosis
A. A.	11	V. cava	Not patch related
L. M.	34	Aortic arch	Aneurysm
L. B.	52	Aortic valve	Stenosis
N. S.	60	Aortic valve	Stenosis

UNIVERSITÄTSMEDIZIN GÖTTINGEN : UMG

Herz Zentrum Göttingen

Matrix-Patch: Göttingen experience

Macroscopic view

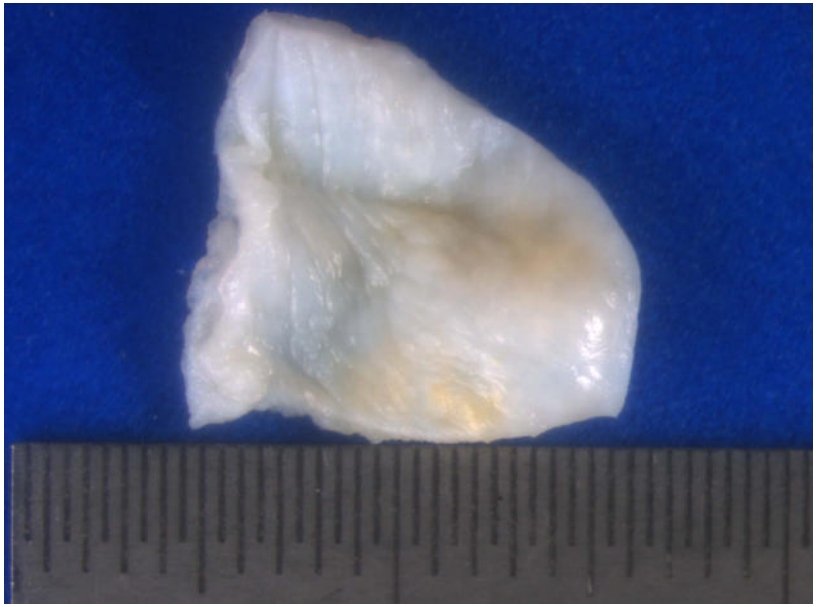

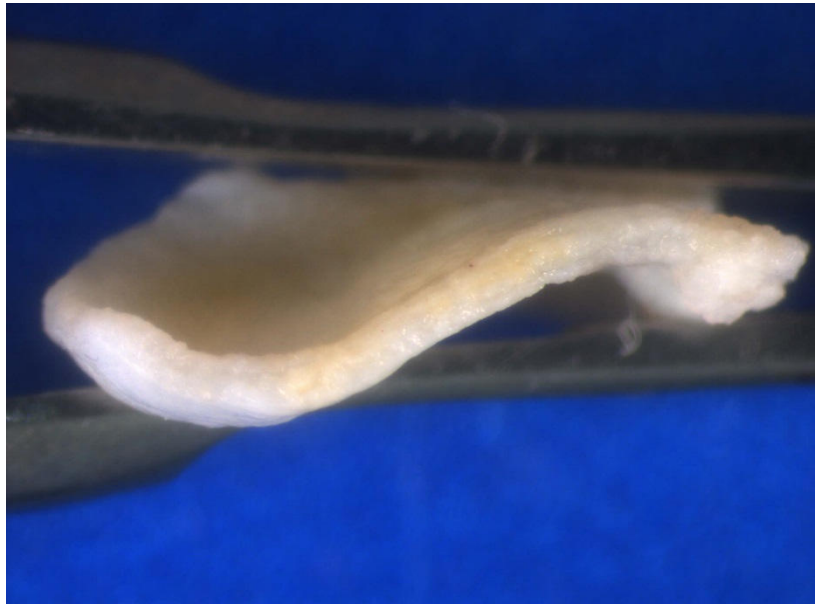

Aortic valve augmented with Matrix Patch (right coronary)
Explantation after 60 months

Matrix-Patch: Göttingen experience

Histology - Immunohistochemistry

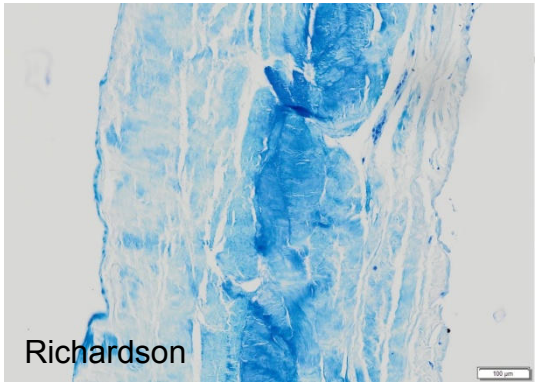

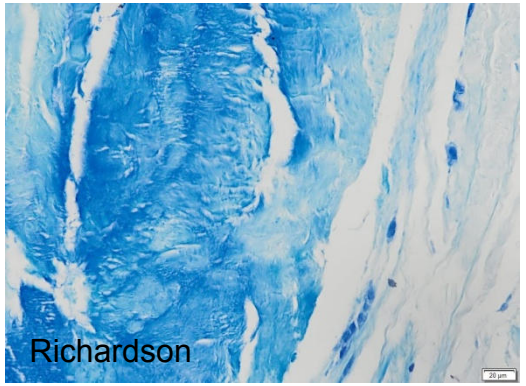

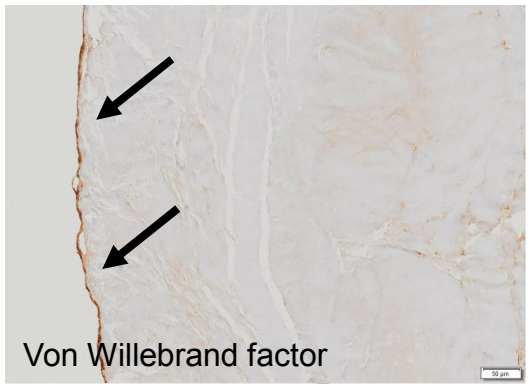

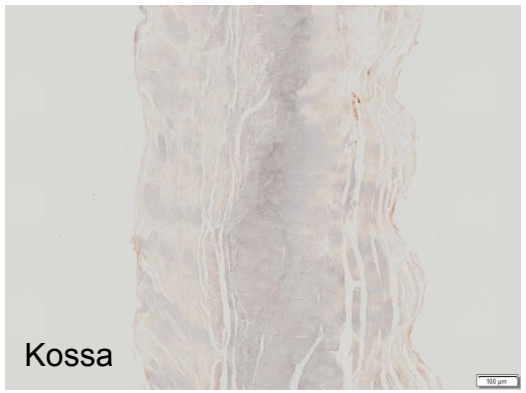

Aortic valve augmented with Matrix Patch (right coronary)
Explantation after 60 months

Matrix-Patch: Göttingen experience

Histology – calcifications, proliferation, cell ingrowth

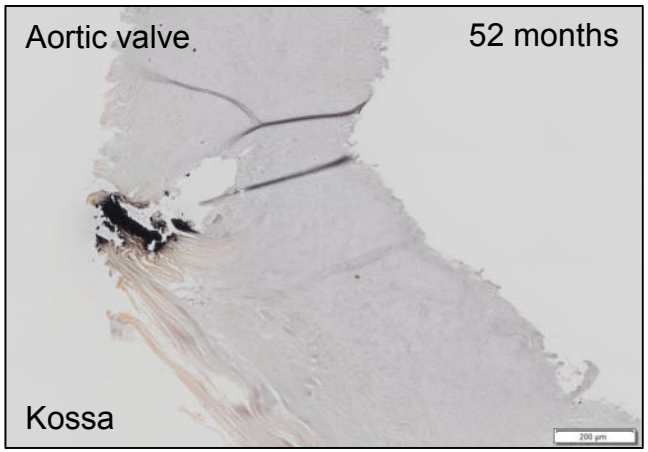

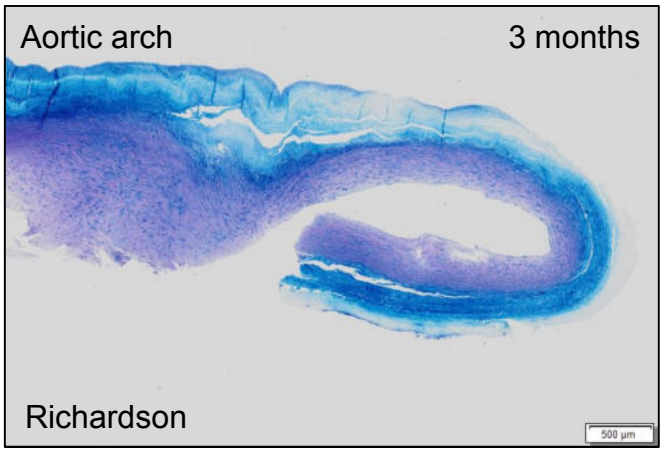

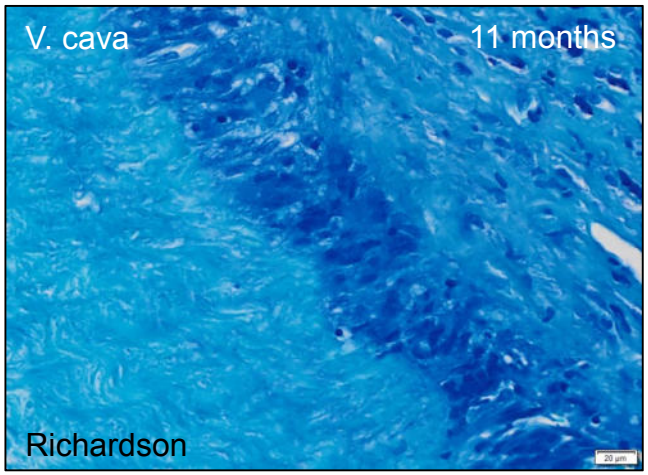

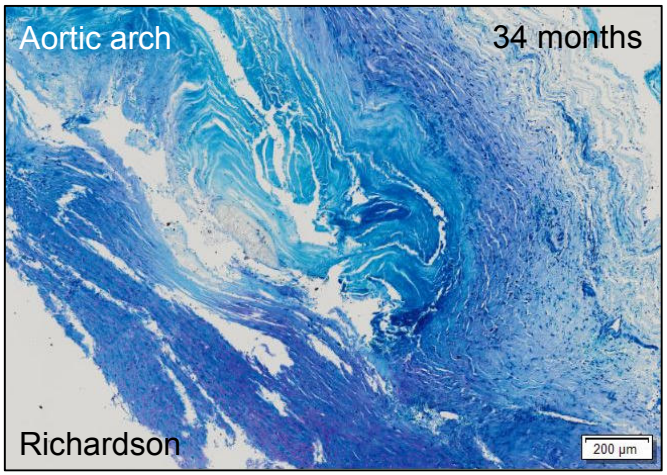

Histopathology of the Matrix-Patch

Summary

- Histology can be helpful
- Patch materials are prone to inflammation, tissue proliferation, and calcification
- Matrix-Patch (implantation time ≤ 5 years)
  - some proliferation
  - formation of macrophage walls
  - few lymphocytic infiltration
  - no significant ingrowth of cells
  - no calcifications



Thank you.

msigler@gwdg.de